



DATE **CLINICAL BACKGROUND & STUDY DETAILS**

4.7.26

PATIENT

Noodle Warble

SPECIES

Feline

BREED

DSH

SEX

FS

AGE

1.1.13

WEIGHT

4lbs

INTERPRETED BY

Maggie Machen Lamy,
DVM, DACVIM
(Cardiology)

HOSPITAL NAME

Cat Sense Feline
Hospital

REFERRING VET

Dr Sinclair

INVOICE

47449

History: Presented for chronic congestion and weight loss. She had been a feral cat that has since been tamed. She often "sounds like an oxygen tank while breathing." Her stomach always make noises. She has recently lost weight. On PE she was very thin with almost no muscling, and she has chronic UR congestion that I believe makes her swallow a lot of air. No heart murmur was ausculted. Her entire GI tract was full of air on the radiograph, especially the stomach. Bloodwork shows a significant non-regenerative anemia, mild azotemia, hyperglobulinemia and an extremely elevated BNP. Was initially started on Azithromycin but was switched to Doxycycline when the anemia was found just in case of an early Mycoplasma Haemofelis.

Pertinent abnormal PE/Chem/CBC/UA Results: HCT=17%, BUN=49, globulins=7.0, BNP=1500

Current medications: Doxycycline 10mg bid, Simethicone infant drops -0.3ml tid-qid

Sedation used: Not required to complete full diagnostic ultrasound.

Pertinent previous ultrasound results: No previous.

STAT: Not requested.

Imaging performed by: Stephanie Warga RDCS, RVT.

RADIOGRAPHIC FINDINGS *NOTE: Images submitted for supplemental information only.

A lateral film is included. Cardiomegaly. No obvious evidence of CHF.

ECHOCARDIOGRAM FINDINGS

2D, m-mode, color flow and doppler imaging is available. The left ventricular wall is decreased in dimension. There is a mildly hyperechoic endocardium consistent with mild fibrosis. The papillary muscles are normal in size and hyperechoic. The LV chamber is moderately dilated with increased sphericity. The LV function is moderately depressed. The left atrium is normal. The right atrium is normal in size. The right ventricle appears normal. The mitral valve is normal in structure and mobility. Trace MR and TR. Blood flow through the LVOT is normal in velocity. The aortic valve is thickened with an irregular appearance and suspect prolapse. Moderate to severe AI. No PI. No pleural or pericardial effusion seen. No obvious cardiac tumors.

CARDIAC CHART

FELINE CARDIAC PARAMETERS	BODY WEIGHT (kg)	HR (BPM)	IVSd (cm) <small>(Moise, Pipers)</small>	LVIDd (cm) <small>(Moise, Pipers)</small>	LVWd (cm) <small>(Moise, Pipers)</small>	FS (%)	EF (%)
NORMAL PARAMETER	-----	150-240	3.5-0.55	<2 (mean 1.5)	3.5-0.55	35-67	80-100
PATIENT	1.8	NM	0.30	2.0	0.31	23	50
FELINE CARDIAC PARAMETERS	LA/AO <small>(Boon)</small>	LA/AO HEART BASE (Swe) <small>(Abbott)</small>	LA 2D short axis Base view (cm) <small>(Abbott)</small>		LVOT VEL (m/s)	RVOT VEL (m/s)	E max (m/s)
NORMAL	<1.5	<1.3	<1.2		<1.6	<1.3	<0.9
PATIENT	NM	1.3	1.3		1.5	0.8	NM

Adapted from June Boon, Veterinary Echocardiography, 1998

Abbott J & MacLean H JVIM 2006;20: 111-119, Moise et al. Am J Vet Res 47:1476, 1986. Pipers et al. Am J Vet Res 40:882, 1979.

INTERPRETATION OF THE FINDINGS & FURTHER RECOMMENDATIONS

Unusual case. The LV appearance is dilated with decreased systolic dysfunction. While a form of DCM is possible, this can also develop secondary to chronic and significant aortic valve insufficiency, which is present. The aortic valve is abnormal and whether this reflects a congenital abnormality or some acquired process is unclear. Certainly, a **baseline BP is strongly recommended**. Despite this, the LA is normal suggesting relatively low risk for complication at this time. No additional structural issues are seen.

Going forward, it is unclear as to the clinical relevance of these findings as rate of progression cannot be determined. Pending BP assessment, an ACE-I is likely reasonable in hopes of decreasing afterload. Pimobendan is also recommended, given the appearance of the LV. No additional medications are necessary at this time.

Prognosis is guarded due to the significance of the changes, although highly variable prior to LA dilation. There will be risk for progression to CHF, development of blood clots and/or sudden death. Serial monitoring is advised.

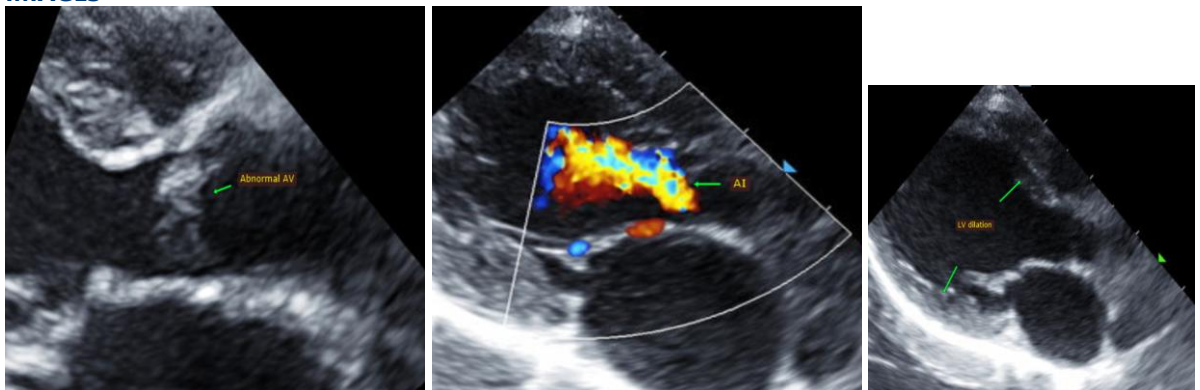
Anesthetic risk is considered mild. IV fluid restriction is advised. Risk for complication with steroid use typically follows LA dilation, which in this case is low. That being said, any cat can experience unexpected signs of intolerance and monitoring of RR/RE is advised particularly in the initiation phase.

PLAN

Pending BP assessment, an ACE-I is recommended (0.5mg/kg PO q12h). Institute Pimobendan 1.25mg PO q12h. Full systemic workup for systemic issues.

Recommend recheck echocardiogram in 6 months to assess for any progressive issues.

IMAGES



The information and recommendations provided are based on the images presented by the referring veterinarian. No evaluation can be communicated regarding pathology that was not visible in the image/video clips provided.

Thank you for this referral. This report was generated using transcription software, and minor dictation errors may be present. If the clinical or image interpretation does not parallel your findings or if I can be of any further assistance, please contact me.

Maggie Machen Lamy, DVM
Diplomate of the American College of Veterinary Internal Medicine (Cardiology)
info@sonopath.com